




U.S. Department of Agriculture
Animal and Plant Health Inspection Service
Wildlife Services

U.S. Government Publication



Organ weights and histopathology of double-crested cormorants (*Phalacrocorax auritus*) dosed orally or dermally with artificially weathered Mississippi Canyon 252 crude oil



Kendal E. Harr^{a,*}, Drury R. Reavill^b, Steven J. Bursian^c, Dave Cacula^d, Fred L. Cunningham^e, Karen M. Dean^d, Brian S. Dorr^e, Katie C. Hanson-Dorr^e, Kate Healy^f, Katherine Horak^g, Jane E. Link^c, Susan Shriner^g, Robert E. Schmidt^b

^a Urika Pathology, Mukilteo, WA 98275 USA

^b Zoo/Exotic Pathology Service, 6020 Rutland Drive #14, Carmichael, CA 95608, USA

^c Department of Animal Science, Michigan State University, 474 South Shaw Lane, East Lansing, MI 48824, USA

^d Abt Associates, 1881 Ninth St., Ste 201, Boulder, CO 80302-5148, USA

^e USDA WS National Wildlife Research Center, P.O. Box 6099, Mississippi State University, Starkville, MS 39762, USA

^f DWH NRDAR Field Office, USFWS, 341 Greeno Road North, Suite A, Fairhope, AL 36532, USA

^g USDA WS National Wildlife Research Center, Fort Collins, CO 80521 USA

ARTICLE INFO

Keywords:

Deepwater Horizon
Avian
Oil
Organ weights
Histopathology

ABSTRACT

A series of toxicity tests were conducted to assess the effects of low to moderate exposure to artificially weathered Deepwater Horizon Mississippi Canyon 252 crude oil on representative avian species as part of the Natural Resource Damage Assessment. The present report summarizes effects of oral exposure ($n = 26$) of double-crested cormorants (DCCO; *Phalacrocorax auritus*) to 5 or 10 ml oil $\text{kg}^{-1} \text{day}^{-1}$ for up to 21 days or dermal application ($n = 25$) of 13 ml oil to breast and back feathers every three days totaling 6 applications in 21 days on organ weights and histopathology. Absolute and relative kidney and liver weights were increased in birds exposed to oil. Additionally, gross and/or histopathologic lesions occurred in the kidney, heart, pancreas and thyroid. Clinically significant renal lesions in the orally dosed birds included squamous metaplasia and increased epithelial hypertrophy of the collecting ducts and renal tubules and mineralization in comparison to controls. Gross cardiac lesions including thin walls and flaccid musculature were documented in both orally and dermally dosed birds and myocardial fibrosis was found in low numbers of dermally dosed birds only. Cytoplasmic vacuolation of the exocrine pancreas was noted in orally dosed birds only. Thyroid follicular hyperplasia was increased in dermally dosed birds only possibly due to increased metabolism required to compensate damaged feather integrity and thermoregulate. Gastrointestinal ulceration was found in orally dosed birds only. There were no significant hepatic histopathologic lesions induced by either exposure route. Therefore, hepatic histopathology is likely not a good representation of oil-induced damage. Taken together, the results suggest that oral or dermal exposure of DCCOs to artificially weathered MC252 crude oil induced organ damage that could potentially affect survivability.

1. Introduction

During the Deepwater Horizon (DWH) oil spill in 2010, many live birds representing at least 93 species were found visibly oiled but not to the extent to cause immediate mortality (Deepwater Horizon Natural Resource Damage Assessment Trustees, 2016). It was of particular

interest to examine the effects of these lower amounts of oil (less than 30% of body coverage) in order to assess avian injury as part of the DWH Mississippi Canyon 252 (MC252) Oil Spill Natural Resource Damage Assessment (NRDA).

Diving birds such as the double-crested cormorant (DCCO; *Phalacrocorax auritus*) are particularly susceptible to oil exposure

* Corresponding author.

E-mail addresses: drharr@urikapathology.com (K.E. Harr), dreavill@zoosexotic.com (D.R. Reavill), bursian@msu.edu (S.J. Bursian), Dave_Cacula@abtassoc.com (D. Cacula), Fred.L.Cunningham@aphis.usda.gov (F.L. Cunningham), kdmdean@gmail.com (K.M. Dean), Brian.S.Dorr@aphis.usda.gov (B.S. Dorr), Katie.C.Hanson-Dorr@aphis.usda.gov (K.C. Hanson-Dorr), katherine_healy@fws.gov (K. Healy), Katherine.E.Horak@aphis.usda.gov (K. Horak), linkj@msu.edu (J.E. Link), Susan.A.Shriner@aphis.usda.gov (S. Shriner), speedy27@cox.net (R.E. Schmidt).

<http://dx.doi.org/10.1016/j.ecoenv.2017.07.011>

Received 14 September 2016; Received in revised form 3 July 2017; Accepted 3 July 2017

Available online 19 July 2017

0147-6513/ © 2017 Elsevier Inc. All rights reserved.

during a spill because they dive through the water, and thus the oil, in order to feed (Szaro et al., 1978). They are therefore likely to be exposed not only dermally, but also by incidental ingestion through attempts to rid their feathers of oil through preening and possibly by ingesting oil through contaminated feedstuffs. In birds, anemia, disrupted feather function, hypothermia, respiratory distress, seizures, diarrhea, hepatic disease and renal disease have all been reported secondary to exposure to petroleum products (Mazet et al., 2002).

The two sets of data reported here address the effects of both oral and dermal oiling on the relevant oil exposure endpoints of organ weights and histopathology in the DCCO.

2. Methods

This study was performed under the authority of USFWS MBPO Federal Permit # MB019065-3, Mississippi and Alabama state (#8017) scientific collection permits, and Institutional Animal Care and Use Committee (IACUC) under NWRC protocol QA-2326. Cunningham et al. (2017, this issue) provides a detailed description of animal capture and handling for the experimental oral and dermal exposure of DCCO to DWH artificially weathered MC252 oil.

2.1. Oral dosing study

Captured DCCOs were randomly assigned to one of three treatment groups: a control group ($n = 8$, 7 male, 1 female) that was fed catfish that had been lightly anesthetized with MS222 and allowed to revive; a group dosed daily with up to 5 ml oil/kg bw/day through provision of oil-containing, lightly anesthetized catfish ($n = 9$, 6 male, 3 female); a group dosed daily with up to 10 ml oil/kg bw/day through provision of oil-containing, lightly anesthetized catfish as described below ($n = 9$, 7 male, 2 female).

2.2. Dermal dosing study

A total of 31 DCCO's were captured and retained in captivity. Birds were allowed to acclimate to captivity for a minimum of 21 days prior to initiation of the study. A total of 25 subadult DCCOs allocated to a control group ($n = 12$, 5 male, 7 female) and an exposed group ($n = 13$, 6 males, 7 females) were used in this trial. DCCOs were assigned to treatment groups based on the results of blood samples collected at the initiation of the three-week quarantine period. Complete blood count (CBC) values were used to ensure equal division of birds with potential health concerns between groups. DCCO's with monocyte counts greater than 2.0×10^9 cells/l were considered abnormal (severe monocytosis); and were divided between control ($n = 4$) and treatment ($n = 3$) groups. Additionally, a small oil spill took place one year prior to the study, not far from where 6 of the DCCOs were collected and were evenly distributed between groups. During the course of the trial, one bird from the control group and two birds from the treatment group died and were not replaced. Therefore, the final number of birds in the control and exposed group was 11 birds each to total 22 in the study. Oil on exposed birds (13 ml) and water on control birds (13 ml) was applied every three days through Day 15 of the trial (on Days 0, 3, 6, 9, 12, and 15). Detailed description of application is available in Cunningham et al. (2017).

2.3. Necropsy

The oral dosing study was terminated at 21 days of exposure and the dermal oiling study was terminated on days 21 and 22 of exposure. All members of the high dose group of the oral study were euthanized by day 18 for humane reasons and so the day 21 sampling was not performed. Final blood samples were obtained (Cunningham et al., 2017), then DCCOs were euthanized by cervical dislocation. Organs were exposed, photographed, then removed, weighed and preserved in 10%

neutral buffered formalin for histological examination.

2.4. Histopathology

Tissues were paraffin embedded, sectioned at approximately 5 μ m, affixed to glass microscope slides and stained with hematoxylin and eosin. Organs were examined by board certified veterinary pathologists in the oral (RES) and dermal (DRR) study. Lesions were graded using the scale 1 = minimal, 2 = mild, 3 = moderate, 4 = severe that both pathologists developed. Hepatic iron was assessed using standard hematoxylin and eosin staining and Prussian blue staining, which is specific for iron, using the same grading used for lesions (Khan and Nag, 1993) and was examined by RES only. Quality assurance was performed by a third boarded pathologist, Dr. Jennifer Brazzell, to insure consistent results.

3. Results

3.1. Mortality

Of the 26 adult, mixed-sex DCCO used in the oral dose study, 16 were euthanized on Day 21. A total of 10 treated DCCOs died or were euthanized within 17 days of the start of the study for humane reasons, including all 9 high dose animals. DCCO began exhibiting clinical signs such as anemia, abnormal feces, lethargy, and behavioral thermogenesis (shivering under a heat lamp) at a total dose of approximately 80 ml/kg and all were dead prior to 200 ml/kg total dose.

Of the 25 subadult, mixed-sex DCCO used in the dermal exposure study one control bird and two treated birds died prior to Day 21 of the study. DCCO began exhibiting clinical signs such as anemia, hematochezia, behavioral thermogenesis, decreased appetite, and lethargy by day 10. One exposed bird died with probable septicemia (underlying etiologic agent not identified). One exposed bird died with no significant lesions that could be assessed as a cause of death. A chronic, necrotizing granuloma was found at the heart base of the control bird at necropsy.

3.2. Absolute and relative organ weights

Absolute and relative kidney weights were significantly greater in orally and dermally dosed DCCOs compared to their respective controls (Fig. 1a and b). Absolute and relative liver weights were significantly greater in DCCOs orally dosed with 5 ml oil kg bw^{-1} day^{-1} and in DCCOs that were dermally oiled compared to controls (Fig. 2a and b). There was no significant difference in absolute or relative (expressed as % body weight) brain, heart or spleen weight in orally or dermally dosed DCCOs compared to controls.

3.3. Histopathology

A number of histological lesions were found in tissues of DCCOs dosed orally or dermally with artificially weathered MC252 oil (Table 1). Organ weights from both exposure groups are summarized in Table 2.

3.3.1. Oral dosing study

Gross pathologic findings in orally dosed birds included enlarged kidneys, hearts that had flaccid musculature, proventricular ulcerative lesions, intestinal edema, yellow bile, and large numbers of intestinal parasite numbers in the low dose group with no to few intestinal parasites in the high dose group. During necropsy of orally dosed birds, blood pooled in the cavities and did not clot after several minutes whereas blood did not pool in control birds. Gonad identification revealed 20 males and 6 females with immature gonads, divided as described in the materials and methods.

Inflammatory renal lesions were common in all groups; however,

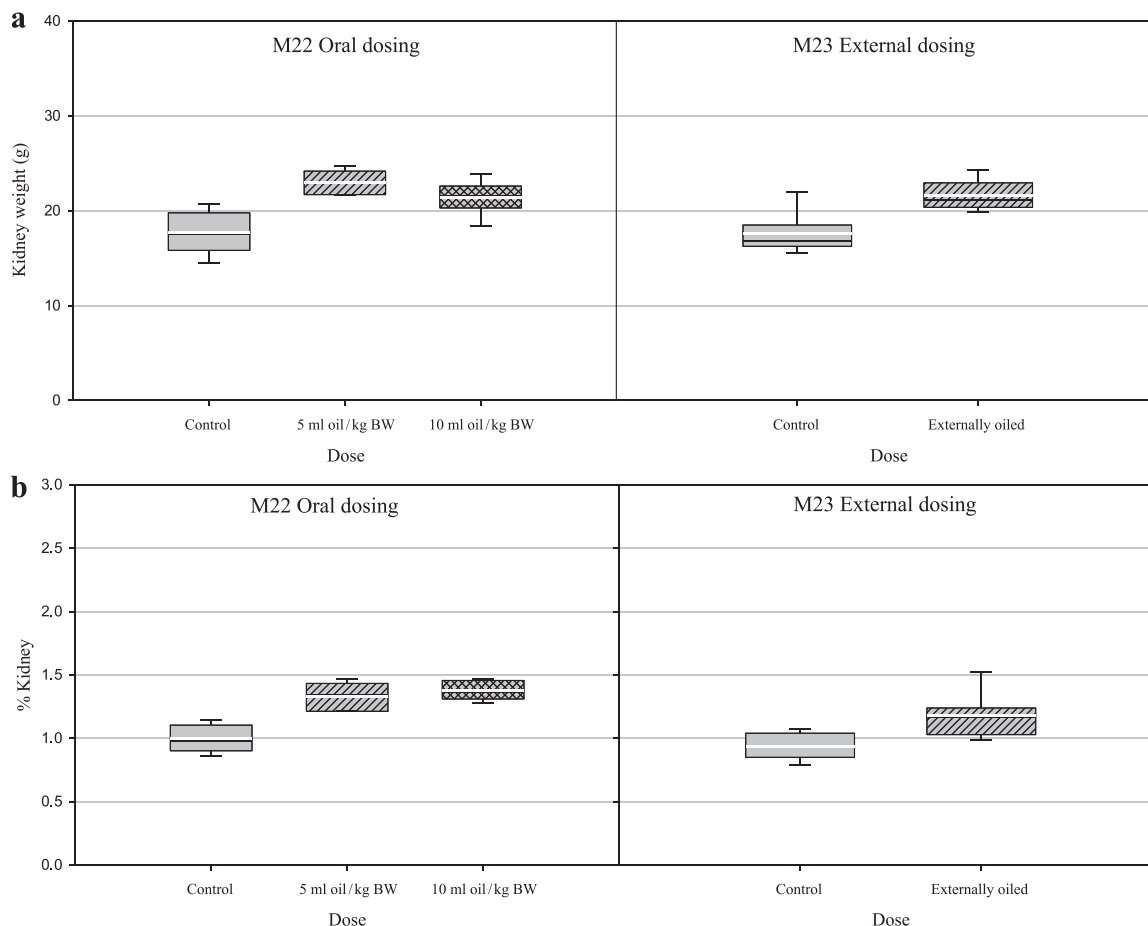


Fig. 1. a) Effect of oral or dermal dosing with artificially weathered MC252 oil on kidney weight in double-crested cormorants (*Phalacrocorax auritus*). The lower and upper boundaries of the boxes indicate the 25th and 75th percentiles, respectively. The black line within the boxes is the median and the white line within the boxes is the mean value. The lower and upper whiskers indicate the 10th and 90th percentiles, respectively. Kidney weight was significantly greater in orally dosed birds ($p = 0.0092$) and dermally oiled birds ($p < 0.0001$) than in controls. **b)** Effect of oral or dermal dosing with artificially weathered MC252 oil on kidney weight relative to body weight in double-crested cormorants (*Phalacrocorax auritus*). The lower and upper boundaries of the boxes indicate the 25th and 75th percentiles, respectively. The black line within the boxes is the median and the white line within the boxes is the mean value. The lower and upper whiskers indicate the 10th and 90th percentiles, respectively. Kidney weight relative to body weight was significantly greater in orally dosed birds ($p = 0.0017$) and in dermally oiled birds ($p = 0.0005$) than in controls.

collecting duct and renal tubule hypertrophy, squamous metaplasia, and mineralization were seen more frequently in histopathology samples from treated birds versus control birds, with the most severe and frequent lesions found in the high dose group. Collecting duct and renal tubule lesions in birds dosed with 10 ml oil kg bw^{-1} day $^{-1}$ and 5 ml oil kg bw^{-1} day $^{-1}$ increased in frequency, distribution, and severity. Periductal inflammation was most commonly described and appeared to involve a major portion of the collecting duct and renal tubule within medullary cones. The type of inflammatory infiltrate varied but was primarily associated with lymphocytes and plasma cells, although heterophils were occasionally seen. Renal coccidiosis was noted with similar frequency in the treated and control groups.

Increased exocrine pancreatic cytoplasmic vacuolation was noted in both the low dose and high dose groups. Amyloidosis was noted in the pancreas of one high dose bird.

Enteric lesions occurred more commonly in birds orally dosed with 10 ml oil kg bw^{-1} day $^{-1}$ compared with the other groups, but similar lesions were found in all groups. Involution of the bursa of Fabricius was noted in both treated and control groups. Gastrointestinal lesions across groups were common and involved primarily low-level parasitism with nematodes (proventriculus, ventriculus, cecum, and cloaca), trematodes (proventriculus), and cestodes (colon). There were few instances of variably severe inflammation of unknown etiology at all levels of the gastrointestinal tract. Gross necropsy reports noted that enteric parasites seemed to be more prevalent in the intestines of birds

dosed with 5 ml kg bw^{-1} day $^{-1}$, although these results are anecdotal as parasite numbers were not quantified. Cytoplasmic vacuolation of exocrine cells was the most common lesion seen in the pancreas, and increased in the oil-dosed birds in comparison to the control birds.

Inflammatory liver lesions were mild, non-specific, and included mild lymphocyte predominant cholangitis, cholangiohepatitis, and hepatitis in all groups. In addition, in many of the birds, hemosiderin-containing macrophages were present in the liver and spleen. Iron staining of the livers revealed minimal hepatic iron staining (graded as 1) in most birds. Moderate staining (graded as 2) was noted in two of the 5 ml oil kg bw^{-1} day $^{-1}$ group birds and in one control bird. There was no observable difference in severity of iron staining of the liver between groups. The splenic lesions seen were most commonly in the 5 ml oil kg bw^{-1} day $^{-1}$ birds. Some of the splenitis was obviously associated with sepsis; however, in some birds there was a more chronic inflammatory infiltrate of undetermined cause.

All other lesions identified in numerous organ systems were similar between the treatment groups. Almost all examined lungs were congested and had airway hemorrhage, which was considered a necropsy artifact. One bird had lesions consistent with bacterial septicemia. One bird in the control group had a focus of mineralization in the brain, which is likely to have been an incidental finding. Additionally, one bird in each group had an esophagitis, which appeared to be a bacterial infection.

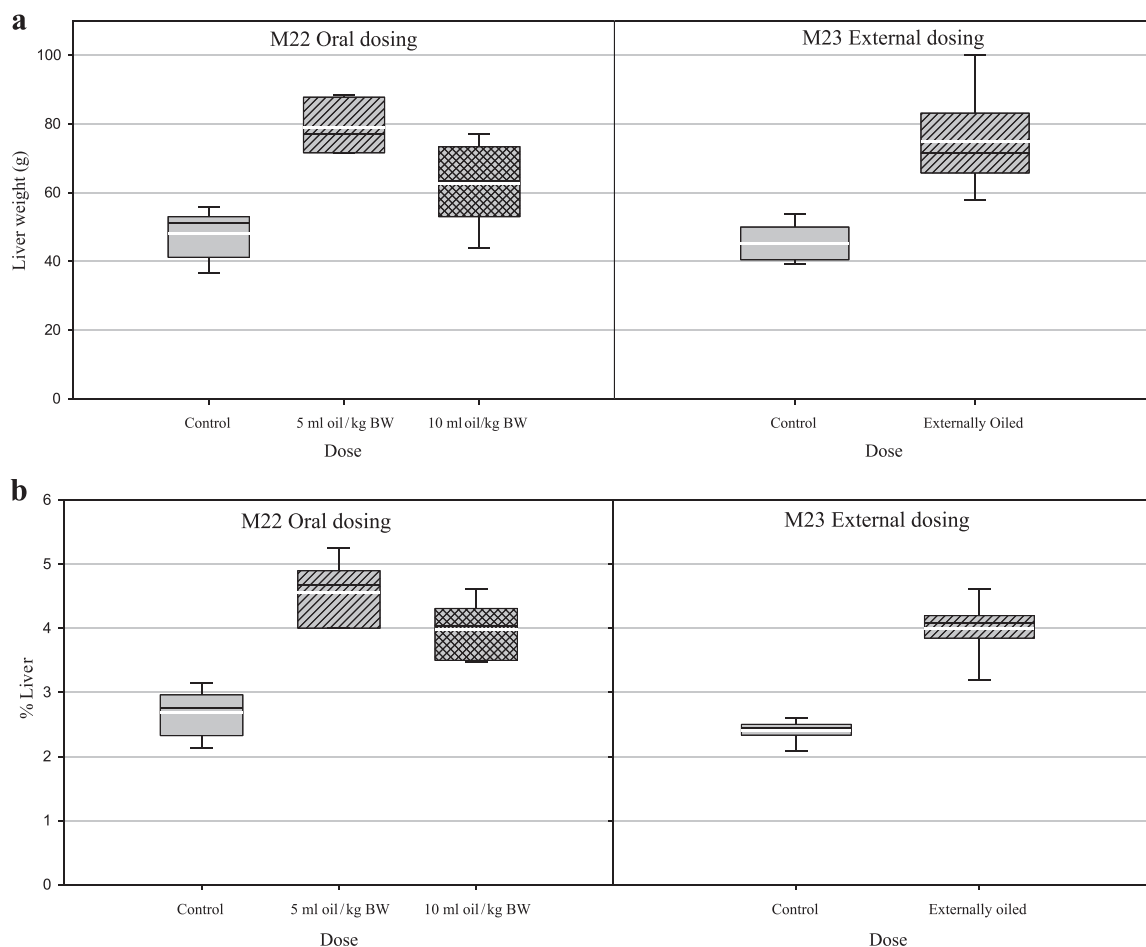


Fig. 2. a) Effect of oral or dermal dosing with artificially weathered MC252 oil on liver weight in double-crested cormorants (*Phalacrocorax auritus*). The lower and upper boundaries of the boxes indicate the 25th and 75th percentiles, respectively. The black line within the boxes is the median and the white line within the boxes is the mean value. The lower and upper whiskers indicate the 10th and 90th percentiles, respectively. Liver weight was significantly greater in birds orally dosed ($p = 0.0012$) with 5 ml oil kg body weight ($\text{bw}^{-1} \text{day}^{-1}$) and in dermally oiled birds ($p < 0.0001$) than in controls. b) Effect of oral or dermal dosing with artificially weathered MC252 oil on liver weight relative to body weight in double-crested cormorants (*Phalacrocorax auritus*). The lower and upper boundaries of the boxes indicate the 25th and 75th percentiles, respectively. The black line within the boxes is the median and the white line within the boxes is the mean value. The lower and upper whiskers indicate the 10th and 90th percentiles, respectively. Liver weight relative to body weight was significantly greater ($p = 0.0006$) in birds orally dosed with 5 ml oil kg body weight ($\text{bw}^{-1} \text{day}^{-1}$) compared to controls. Liver relative to body weight was significantly greater ($p < 0.0001$) in dermally oiled birds than in controls.

3.3.2. Dermal dosing study

Gonad identification revealed 5 males and 7 females in the control group and 6 males and 7 females in the treated group. No developed ovaries were found in any of the females at necropsy indicating a subadult classification. In the dermal dosing trial, there did not appear to be any difference in the number or severity of lesions between the control and treated groups with the exception of the heart and the thyroid gland, which were somewhat increased in treated birds.

Renal inflammatory lesions were evenly distributed between both groups as were the four of birds with intraepithelial coccidia. Lesions were characterized by a lymphoplasmacytic inflammatory infiltrate. One control bird had myocarditis and sequelae while four dermally oiled birds had cardiac lesions including myocardial fibrosis and bacterial granuloma. The thyroid gland did seem to have some differences between the two treatment groups, with the dermally oiled birds being more affected compared to controls. A diagnosis of hyperplastic goiter (follicular hyperplasia) was based on the presence of multiple small thyroid follicles, many of which were lined by cuboidal follicular epithelium and were devoid of colloid. While the occurrence of this condition could depend on season and/or reproductive activity of the birds, there were only two control birds with thyroid changes compared to eight in the dermally oiled group. The lesions are most suggestive of goiter and could be due to a diet having either goitrogenic material within it or low iodine levels.

Both the control and oiled groups of DCCOs had intra-epithelial nematodes recognized within the cloaca, although they were not quantified. In addition, both groups had equal numbers of birds that were supporting a moderate to severe nematode related lesion of the ventriculus with granulomas forming within the submucosa, as well as nematode free lumens. The proventriculus was similar between the control and oil-dosed group in terms of supporting intraluminal nematodes and variable amounts of inflammation.

A reactive spleen, seen in approximately half of the control and treated birds, was based on the identification of lymphoid follicles identified within the splenic architecture. The liver lesions as well as the reactive spleen could easily be accounted for by the nonspecific enteritis as well as the nematode parasitism recognized within the gastric sections.

There were more severe lung lesions noted in the control group of which at least one was a bronchopneumonia with granulomas. In one of the oil-dosed birds, there were multiple fungal granulomas as well as granulomatous inflammation in an air sac of a second oiled bird.

4. Discussion

Many lesions, especially inflammatory lesions, recognized at gross and histologic examination were similar morphologically in both control and treated birds and most likely represented background disease

Table 1

Summary of histological lesions found in tissues of double-crested cormorants (*Phalacrocorax auritus*) dosed orally or dermally with artificially weathered MC252 oil. Lesions were graded using the scale 1 = minimal, 2 = mild, 3 = moderate, 4 = severe.

Tissue/Treatment	Lesion description	Lesion distribution - qualitative	Lesion grade - qualitative	Mean lesion grade - quantitative	Number of animals affected
Kidney					
Oral control	lymphoplasmacytic interstitial nephritis	multifocal	minimal to moderate	1.9	4/8
	periductal inflammation	diffuse	minimal to moderate	1.9	4/8
	interstitial abscess formation	multifocal	minimal	1.0	1/8
	tubular epithelial hypertrophy	multifocal	minimal to moderate	2.0	1/8
5 ml oil kg bw ⁻¹	ureteral mucosal hyperplasia, ureteral inflammation, with intraluminal bacteria and inflammatory cells	focal	moderate	3.0	1/8
	lymphoplasmacytic interstitial nephritis	multifocal to confluent	moderate to severe	3.5	1/9
	periductal inflammation	multifocal to diffuse	minimal to moderate	1.8	3/9
	bacteremia	multifocal to confluent	moderate	3.0	1/9
	ductal epithelial hypertrophy	focal	mild	2.0	1/9
	fibrin thrombi/emboli	multifocal	moderate to severe	3.5	1/9
	hypertrophy and squamous metaplasia	multifocal	severe	4.0	1/9
	mineralization	focal	minimal to mild	1.3	2/9
	peritubular inflammation	multifocal	minimal to mild	1.7	3/9
	renal coccidiosis	multifocal to confluent	moderate	3.0	1/9
10 ml oil kg bw ⁻¹	periductal inflammation	focal to multifocal	mild to severe	3.0	2/9
	Renal tubule epithelial hypertrophy	focal to multifocal	moderate to severe	3.5	2/9
	ductal epithelial hypertrophy	focal	severe	4.0	1/9
	mineralization	focal to multifocal	minimal to mild	1.3	4/9
	squamous metaplasia	focal to multifocal	mild	2.0	5/9
	tubular epithelial hypertrophy	focal to multifocal	mild to severe	3.0	3/9
	lymphoplasmacytic interstitial nephritis	multifocal	minimal to moderate	2.1	8/11
Dermal control	renal coccidiosis	–	–	–	2/11
	lymphoplasmacytic interstitial nephritis	focal - multifocal	minimal to mild	1.8	8/11
Treated	renal coccidiosis	focal	mild	2.0	1/11
Heart					
Oral control	chronic myodegeneration and fibrosis	focal	moderate	3.0	1/8
	myocarditis	focal	minimal	1.0	2/8
5 ml oil kg bw ⁻¹	bacteremia	multifocal	mild	2.0	1/9
	endocarditis	multifocal to confluent	mild	2.0	1/9
	mineralization	multifocal	mild	2.0	1/9
	myocarditis	multifocal	mild	2.0	1/9
	myofiber degeneration/hemorrhage	multifocal	mild to moderate	2.5	1/9
10 ml oil kg bw ⁻¹	no lesions	–	–	–	0/9
Dermal control	epicardial hemorrhage	focal	minimal	1.0	1/11
	myocardial hemorrhage	multifocal	mild	2.0	1/11
	myocarditis, lymphoplasmacytic	focal	minimal	2.0	1/11
Treated	bacterial granulomas	multifocal	moderate	3.0	1/11
	myocardial fibrosis	multifocal	mild to moderate	2.3	3/11
	septic and suppurative thrombi	focal	mild	2.0	1/11
Pancreas					
Oral control	no lesions	–	–	–	0/8
5 ml oil kg bw ⁻¹	cytoplasmic vacuolization	focal to multifocal	minimal to moderate	1.4	4/9
10 ml oil kg bw ⁻¹	interstitial pancreatitis	multifocal to confluent	moderate	3.0	1/9
	amyloidosis	multifocal to confluent	moderate	3.0	1/9
	cytoplasmic vacuolization	multifocal to diffuse	mild to moderate	3.0	3/9
	zymogen depletion	diffuse	mild	2.0	1/9
Dermal control	no lesions	–	–	–	0/11
Treated	no lesions	–	–	–	0/11
Thyroid gland					
Oral control	follicular hyperplasia	multifocal	moderate	3.0	1/8
	colloid atrophy	multifocal to confluent	moderate	3.0	1/8
5 ml oil kg bw ⁻¹	follicular colloid atrophy	diffuse	mild	2.0	1/9
	follicular hyperplasia	diffuse	mild	2.0	1/9
	colloid atrophy	diffuse	moderate	3.0	1/9
10 ml oil kg bw ⁻¹	no lesions	–	–	–	0/9
Dermal control	follicular hyperplasia	–	mild	2.0	2/11
Treated	follicular hyperplasia	–	minimal to moderate	2.2	6/11
Esophagus					
Oral control	no lesion	–	–	–	0/8

(continued on next page)

Table 1 (continued)

Tissue/Treatment	Lesion description	Lesion distribution - qualitative	Lesion grade - qualitative	Mean lesion grade - quantitative	Number of animals affected
5 ml oil kg bw ⁻¹	esophagitis	multifocal	mild to moderate	2.5	1/9
10 ml oil kg bw ⁻¹	no lesion	–	–	–	0/9
Dermal control	no lesion	–	–	–	0/11
Treated	no lesion	–	–	–	0/11
Proventriculus					
Oral control	nematodiasis	focal	minimal	1.0	2/8
	proventriculitis	focal to multifocal	moderate to severe	3.3	2/8
	serositis	focal to multifocal	mild to moderate	2.7	3/8
5 ml oil kg bw ⁻¹	nematodiasis	focal to multifocal	mild to severe	3.2	3/9
	proventriculitis	focal	severe	4.0	2/9
	serositis	multifocal	moderate to severe	3.3	2/9
	glandular dilatation	multifocal	moderate to severe	3.8	2/9
	mucosal hypertrophy/hyperplasia	focal	severe	4.0	1/9
	trematodiasis	focal	mild to moderate	2.8	2/9
10 ml oil kg bw ⁻¹	nematodiasis	focal	mild to severe	3.5	4/9
	proventriculitis	focal to multifocal	mild to severe	3.1	4/9
	glandular dilatation	focal	severe	4.0	2/9
	trematodiasis	focal	moderate	3.0	1/9
	mucosal erosion	multifocal to diffuse	severe	4.0	2/9
	myositis	multifocal	moderate to severe	3.5	1/9
Dermal control	nematodiasis	–	moderate	3.0	3/11
	proventriculitis	diffuse to multifocal	mild to moderate	2.7	3/11
	interstitial granulomas	multifocal	mild	2.0	1/11
	mucosal granulomas	multifocal	moderate	3.0	1/11
Treated	nematodiasis	focal	minimal to mild	1.7	3/11
	proventriculitis	focal	mild to moderate	2.5	2/11
	serositis, lymphoplasmacytic gastritis	–	mild	2.0	1/11
	gastritis	focal	–	2.0	1/11
Ventriculus					
Oral control	nematodiasis	multifocal	moderate	3.0	2/8
	ventriculitis	multifocal to confluent	mild to severe	3.3	6/8
5 ml oil kg bw ⁻¹	nematodiasis	multifocal	mild to severe	2.8	6/9
	ventriculitis	multifocal to confluent	mild to severe	2.8	8/9
	myositis	multifocal to confluent	severe	4.0	1/9
10 ml oil kg bw ⁻¹	ventriculitis	multifocal	moderate	3.0	1/9
	serositis	multifocal	mild	2.0	1/9
Dermal control	nematodiasis	–	moderate	3.0	2/11
	ventriculitis	diffuse	severe	3.3	4/11
	leiomyositis	multifocal to diffuse	mild to severe	3.0	4/11
	lymphoplasmacytic leiomyositis	multifocal	mild	2.7	3/11
Treated	nematodiasis	–	moderate	3.2	5/11
	ventriculitis	multifocal	severe	3.3	4/11
	submucosal granulomas	multifocal	moderate	3.0	2/11
	granulomatous leiomyositis	multifocal	severe	4.0	2/11
Cecum					
Oral control	typhlitis	diffuse	moderate to severe	3.5	1/8
5 ml oil kg bw ⁻¹	nematodiasis	multifocal	moderate	3.0	1/9
	typhlitis	multifocal to confluent	moderate to severe	3.5	2/9
10 ml oil kg bw ⁻¹	no lesions	–	–	–	0/9
Small intestine					
Oral control	enteritis	multifocal	minimal to mild	1.5	1/8
5 ml oil kg bw ⁻¹	no lesions	–	–	–	0/9
10 ml oil kg bw ⁻¹	crypt necrosis	multifocal	minimal to mild	1.2	3/9
	crypt necrosis/mineralization	multifocal	mild	2.0	1/9
	enteritis	multifocal to diffuse	minimal to severe	2.8	2/9
	villar atrophy/effusion	diffuse	mild	2.0	1/9
Dermal control	enteritis, lymphoplasmacytic	diffuse	mild	2.0	2/11
	enteritis, subacute	diffuse	mild to moderate	2.3	7/11
	nematodiasis	–	mild	2.0	1/11
Treated	enteritis, lymphoplasmacytic	diffuse	mild	2.0	2/11
	enteritis, subacute	diffuse	mild to moderate	2.5	4/11
Colon					
Oral control	cestodiasis	multifocal	mild to moderate	2.5	1/8
	colitis	diffuse	moderate to severe	3.5	1/8
5 ml oil kg bw ⁻¹	cestodiasis	focal	mild	2.0	1/9
10 ml oil kg bw ⁻¹	crypt necrosis	multifocal	minimal	1.0	1/9
Cloaca/Bursa of Fabricius					

(continued on next page)

Table 1 (continued)

Tissue/Treatment	Lesion description	Lesion distribution - qualitative	Lesion grade - qualitative	Mean lesion grade - quantitative	Number of animals affected	
Oral control	nematodiasis	multifocal	minimal to severe	2.8	6/8	
	bursal depletion	diffuse	minimal to severe	2.5	2/8	
	5 ml oil kg bw ⁻¹	nematodiasis	multifocal to diffuse	minimal to severe	2.4	7/9
		bursal depletion	diffuse	severe	4.0	2/9
		bursal involution	diffuse	moderate to severe	3.5	2/9
10 ml oil kg bw ⁻¹	nematodiasis	multifocal	minimal to moderate	1.8	3/9	
	bursal involution	diffuse	moderate to severe	3.8	2/9	
Dermal control	nematodiasis	multifocal	minimal to moderate	2.1	11/11	
	bursal depletion	–	mild to moderate	2.5	2/11	
Treated	nematodiasis	multifocal	minimal to moderate	2.1	9/11	
	no lesions	–	–	–	0/11	
Brain						
Oral control	mineralization	focal	mild	2.0	1/8	
5 ml oil kg bw ⁻¹	no lesions	–	–	–	0/9	
10 ml oil kg bw ⁻¹	no lesions	–	–	–	0/9	
Dermal control	no lesions	–	–	–	0/11	
Treated	hemorrhage	multifocal	moderate	3.0	1/11	
Liver						
Oral control	hemosiderin - containing macrophage accumulation	multifocal	minimal to mild	1.1	4/8	
	cholangiohepatitis	multifocal	minimal to mild	1.5	6/8	
	cholangitis	multifocal	minimal to mild	1.3	2/8	
5 ml oil kg bw ⁻¹	hemosiderin - containing macrophage accumulation	multifocal	minimal to mild	1.1	5/9	
	cholangiohepatitis	multifocal	minimal to mild	1.5	7/9	
	cholangitis	multifocal	mild	2.0	1/9	
	embolization/thrombosis	multifocal	severe	4.0	1/9	
	hepatitis	multifocal	minimal to mild	1.5	1/9	
	macrophage accumulation	multifocal	minimal	1.0	1/9	
10 ml oil kg bw ⁻¹	hemosiderin - containing macrophage accumulation	multifocal	minimal to mild	1.5	1/9	
	cholangitis	multifocal	minimal to mild	1.3	4/9	
	hepatitis	multifocal	mild	2.0	1/9	
	hepatocyte karyomegaly	multifocal	mild to moderate	2.5	1/9	
	vacuolar hepatopathy	diffuse	mild	2.0	1/9	
	cholangiohepatitis	–	moderate	3.0	1/11	
Dermal control	cholangitis	multifocal	mild to moderate	2.3	8/11	
	cholangiohepatitis	–	moderate	3.0	1/11	
Treated	cholangitis	multifocal	mild	2.0	4/11	
	hepatitis	multifocal	mild	2.0	3/11	
	hepatitis	multifocal	mild	2.0	3/11	
Spleen						
Oral control	hemosiderin - containing macrophage accumulation	multifocal	minimal to mild	1.5	1/8	
5 ml oil kg bw ⁻¹	embolization/thrombosis	multifocal	severe	4.0	1/9	
	lymphoid depletion	diffuse	mild	2.0	1/9	
	serositis	multifocal	mild to moderate	2.5	1/9	
	splenitis	diffuse	mild to severe	2.8	3/9	
	vasculitis	multifocal	moderate	3.0	1/9	
	no lesions	–	–	–	0/9	
10 ml oil kg bw ⁻¹	reactive spleen	–	mild to moderate	2.5	6/11	
Dermal control	plasmacytic histiocytic splenitis	–	moderate	3.0	1/11	
	reactive spleen	–	mild to moderate	2.0	5/11	
Lung						
Oral control	congestion	diffuse	mild to severe	2.9	8/8	
	hemorrhage	multifocal	moderate to severe	3.6	8/8	
5 ml oil kg bw ⁻¹	congestion	diffuse	mild to severe	2.6	9/9	
	embolic pneumonia	diffuse	severe	4.0	1/9	
	hemorrhage	multifocal	mild to severe	3.5	8/9	
10 ml oil kg bw ⁻¹	congestion	diffuse	mild	2.0	1/9	
Dermal control	nodular lymphoplasmacytic peribronchitis	multifocal	mild	2.0	2/11	
Treated	granulomatous pneumonia	multifocal to coalescing	moderate	3.0	1/11	

in a wildlife population. While the presence of active disease in a wildlife population accurately reflects field conditions, it makes differentiation of subtle oil-induced damage impossible. Some of the confounding factors that may preclude oil-induced lesion evaluation include parasite loads in the birds (metazoans in the digestive tract and protozoans in the kidneys) that can account for some lesions

(gastroenteritis, hepatitis, and various lesions in the kidneys) in both control and treatment groups. While there was a subjective evaluation that oil may impact the number of parasites, this was never quantified.

Table 2

Absolute organ weights in double crested cormorants (*Phalacrocorax auritus*) orally or dermally dosed with artificially weathered MC252 oil.

Dose	Adrenals (g)	SE	Brain (g)	SE	Heart (g)	SE	Kidneys (g)	SE	Liver (g)	SE	Spleen (g)	SE	Thyroids (g)	SE
<i>Orally dosed cormorants</i>														
Control	0.584	0.045	10.47	0.22	18.59 ^A	0.90	17.75 ^A	1.03	48.26 ^A	2.90	0.87	0.08	0.184	0.034
n	6		5		6		5		6		6		5	
5 ml oil/kg BW	0.900	0.072	9.39	0.40	21.58 ^{AB}	2.20	22.07 ^B	0.76	75.47 ^B	4.08	0.81	0.13	0.233	0.035
n	6		6		6		6		6		5		6	
10 ml oil/kg BW	0.700	0.163	9.79	0.27	18.90 ^A	1.13	21.41 ^B	0.74	62.65 ^{AB}	4.92	0.58	0.17	0.149	0.014
n	6		6		6		6		6		6		6	
p-value	0.3032		0.1828		0.0381		0.0009		0.0002		0.2075		0.2330	
<i>Dermally dosed cormorants</i>														
Control	0.664 ^A	0.029	9.07	1.02	20.2	0.82	17.6 ^A	0.58	45.3 ^A	1.47	1.00	0.10	0.195	0.020
n	11		11		11		11		11		11		11	
Oiled	0.808 ^B	0.047	7.59	0.48	21.4	1.37	21.6 ^B	0.44	74.8 ^B	3.91	0.80	0.05	0.185	0.027
n	11		11		11		11		11		11		11	
p-value	0.0221		0.2264		0.4902		< 0.0001		< 0.0001		0.0951		0.7793	

^{AB}Within study columns means with different superscript letter are significantly different at stated p value.

4.1. Oral dosing study

The increased collecting renal tubule epithelial hypertrophy, periductular and peritubular inflammation, and squamous metaplasia in the 10 ml oil kg bw⁻¹ day⁻¹, as well as renal mineralization that would be expected with an irritant toxicant, provides at least a partial explanation for the increase in absolute and relative kidney weights. Squamous metaplasia can be associated with chronic irritation and inflammation as well as vitamin A deficiency. The significant increase in absolute and relative kidney weights in the present oral dosing study supports renal dysfunction from structural changes, including edema, inflammation, necrosis, or other damage. Statistically significant uraemia (Dean et al., 2017, this issue) found in a dose response pattern in orally dosed birds indicates that the tubular architectural changes had functional significance and were a cause of injury. Dean et al. also documented uraemia and hyperphosphatemia at levels indicating renal dysfunction. While no glomerular lesions were documented upon histopathology, it is likely that function decreased before architecture changed in this short 21 day study. The presence of inflammatory and proliferative lesions localized to the renal tubules and ductules was consistent with that previously reported in oil exposed birds and was consistent with a toxic insult. This architectural evidence of damage to the tubules and collecting ducts could also contribute to the decrease in sodium and chloride found in these birds, similar to the Western Sandpiper electrolyte dyscrasia (Dean et al., 2017, this issue; Maggini et al., 2017, this issue) as the ducts and tubules are the resorption site for these electrolytes. Western Sandpipers (*Calidris mauri*) also exposed to the same weathered MC 252 crude oil had evidence of interrenal cell hypertrophy consistent with that found in the literature (Bursian et al., 2017, this issue; Mazet, 2002). Cassin's auklets (*Ptychoramphus aleuticus*) exposed to oil via dermal application and common murrelets (*Uria aalge*) that were recovered from an area affected by a spill of bunker C fuel oil had renal tubular necrosis (Fry and Lowenstine, 1985), and mallard (*Anas platyrhynchos*) ducklings fed a diet containing 5.0% South Louisiana crude had tubular inflammation and degeneration in the kidney (Szaro et al., 1978). Exposure to oil and its metabolic products induces an immune and renal cellular response to damage in the kidney while the bone marrow is intact. The inflammatory and cellular changes in this study were consistent with those reported in the literature.

Gross necropsy findings of “flabby” or “flaccid” hearts suggested cardiac damage. However, as expected, standard fixation procedures and hematoxylin and eosin staining were insufficient to determine the full extent of damage, resulting in false negative results. For further discussion of cardiac dysfunction, please see Harr (2017b, this issue).

In this oral dosing study, pancreatic lesions were present only in oil-dosed birds and included cytoplasmic vacuolation of exocrine cells (5 ml oil kg bw⁻¹ day⁻¹ group = 5; 10 ml oil kg bw⁻¹ day⁻¹ group =

3), amyloidosis (10 ml oil kg bw⁻¹ day⁻¹ group = 1) and zymogen depletion (10 ml oil kg bw⁻¹ day⁻¹ group = 1). In avian species, cytoplasmic vacuolation have been reported in association with selenium and vitamin E deficiency, and zinc and cadmium toxicity. Zinc concentration in MC252 weathered oil was 0.92 mg/kg and cadmium concentration was 0.05 mg/kg (Forth et al., 2017). Tissue concentrations were unfortunately not analyzed. The authors hypothesize that pancreatic changes were due to these compounds as postulated in the literature but other components of the crude oil may have contributed to the cytoplasmic vacuolation in the pancreas. Zymogen depletion has been associated with zinc toxicity in the waterfowl as well as degeneration, necrosis or ductular hyperplasia (Sileo et al., 2003). However, ductular change was not noted in the cormorant pancreatic tissues in this study. Amyloidosis encompasses a collection of diseases characterized by the abnormal accumulation of amyloid proteins in tissues. In birds, acquired amyloidosis may occur subsequent to chronic inflammation or infection, enteric parasitism, aging, and stress (Landman et al., 1998). Because the birds in this study were wild caught, variations in extent of infections, enteric parasitism, age and stress are likely. Therefore, differences in these endpoints may be artifacts of life history rather than oil exposure.

There were significant differences in absolute and relative liver weight with minimal histopathologic changes which generally occurred in birds from all three groups; despite statistically significant changes in hepatic biochemical endpoints including decreased AST, ALT, and GGT activities (Dean et al., 2017). The increases in liver weight could indicate edema, inflammatory infiltrate, hypertrophy/hyperplasia, or similar potential changes because of oxidative damage (Duerr, 2013). In the oral dosing study, when histopathologic lesions were compiled, there was no microscopic explanation for the marked increase in gross weight of the liver normalized to body weight. Western Sandpipers (*Calidris mauri*) also exposed to the same weatherer MC 252 crude oil had increased absolute liver weight, no evidence of hemosiderosis in treated birds, and significant evidence of hepatic oxidative damage (Bursian et al., 2017, this issue; Pritsos et al., 2017, this issue).

Increases in liver weight have been reported in prior avian oil exposure studies. Holmes et al. (1978) reported that adult Pekin ducks consuming approximately 6 ml day⁻¹ of South Louisiana crude had increased relative liver weights compared to controls, but relative liver weights of ducks consuming 6 ml of Kuwait crude were comparable to control weights. Herring gull chicks administered a single oral dose of 0.3 ml kg bw⁻¹ of Kuwait or South Louisiana crude oil had increased liver weights when necropsied nine days later (Miller et al., 1978). An increase in liver weight of herring gull chicks receiving five daily oral doses of 10 ml kg bw⁻¹ day⁻¹ of Prudhoe Bay crude oil was reported by Peakall et al. (1989), and mallard ducklings fed diets containing 2.5% and 5.0% South Louisiana crude oil for eight weeks had

significant increases in liver weight (Szaro et al., 1978). Both the Miller et al. (1978) and Peakall et al. (1989) reported that the hepatic activity of mixed function oxidase enzymes was significantly increased in the absence of hepatic pathology, suggesting that the increase in liver weight was a compensatory metabolic response.

Szaro et al. (1978) reported that liver lesions in ducklings fed oil-containing feed were subtle, consisting of generally minimal hypertrophy and vacuolation of hepatocytes and bile duct proliferation which is consistent with that found in this study. Leighton (1986) reported that the most predominant lesion in the livers of herring gull chicks and Atlantic puffin nestlings dosed daily with 10 ml kg bw⁻¹ of Prudhoe Bay crude oil consisted of enlarged Kupffer cells that were filled with gold-brown pigment indicative of hemosiderin and phagocytized erythrocytes. Necrosis of individual hepatocytes and apoptosis were prevalent in the gulls. Hepatic hemosiderosis in oil-exposed birds was also reported by Pattee and Franson (1982), Fry and Lowenstine (1985), and Yamato et al. (1996). In the present oral dosing study, although anemia was present in most treated birds and packed cell volume (PCV) decreased by 50% in six birds in the study (Harr et al., 2017b), hemosiderosis was minimal. There was a mild increase in probable hemosiderin in the 5 ml kg bw⁻¹ day⁻¹ group only. The intestinal erosion noted in the gastrointestinal tract was consistent with clinical observations of abnormal feces. It is possible that iron was not accumulating in hepatocytes as much of the iron in RBC were lost due to external hemorrhage in hematochezia or hematuria. Coagulopathy was also documented in the cormorants using an activated clotting time analysis (Harr et al., 2017a) and so erosion did not have to be present for blood loss to occur.

It should be noted that the oral high dose group consistently had smaller and fewer inflammatory lesions throughout the body than did either the control or low dose group (Table 1). This decrease in inflammatory cells and lesions was evidenced in the kidney, liver, heart, pancreas, and throughout the GI tract. Oil-induced oxidative damage of proliferative hemoprogenitors in the bone marrow has long been documented in mammals and more recently decreased cell mediated immune response has been documented in birds (Olsgard et al., 2008). This finding indicates that immunocompromise when fighting disease expected in wild populations may contribute to morbidity and mortality in oil intoxicated birds. In addition, a decrease in RBC hemoprogenitors in the bone marrow would also contribute to anemia including the severe anemia found in the high dose group in this study (Harr, 2017a, this issue). Indeed, the moderate to severe anemia in these birds was found to be poorly compensated when reticulocytes and rubricytes were evaluated adding further evidence that oil-induced bone marrow damage contributes to not only immunocompromise but decreased oxygen transport due to anemia. Unfortunately, bone marrow was not evaluated in either study. Decreased inflammatory response and decreased hemoglobin was also found in Western Sandpipers (*Calidris mauri*) exposed to the same weathered MC252 crude oil (Bursian et al., 2017) indicating that this response is consistent across bird species tested.

4.2. Dermal dosing study

Dermal dosing primarily resulted in feather damage and presumably less internal oil exposure compared to the orally dosed birds (Cunningham et al., 2017; Dean et al., 2017, this issue). There were two organs which had histologic differences which should be further explored: the heart and the thyroid gland.

While three exposed birds were found to have myocardial fibrosis, this was documented in only one control bird with myocarditis. We postulate that fibrosis (scar tissue) was beginning to form as a healing response to oxidative damage documented in the bird's liver and RBC (Pritsos et al., 2017; Harr et al., 2017a, 2017b). Cardiomyocytes have a high concentration of mitochondria due to their high metabolic state and are sensitive to oxidative damage. (Giordano, 2005) Myocardial

fibrosis is discussed in Harr et al. (2017b) and highlights the need for evaluation of collagen structure in the hearts of oil exposed birds. Unfortunately, no funding was allocated by USFWS for special stains for collagen at the time of this study. Additionally, as collagen changes and fibrosis represent very chronic changes, it is possible that the severity and numbers of animals with histopathologic evidence of structural changes would increase in a longer duration study.

More birds with thyroid gland follicular hyperplasia were present in the dermally dosed group than in the control group. Hypertrophy and hyperplasia of the follicular epithelial cells may be in response to direct effects of crude oil constituents on the thyroid gland (BaJaJ et al., 2016) or increased need for thyroid hormones. Feather damage reduces insulation quality and increases metabolic heat production. Energy intake by feather damaged birds is higher than normal feathered birds to compensate for the increased metabolic heat production (Mazet et al., 2002). The thyroid gland is a critical organ for maintaining general metabolic rate (Olson et al., 1999). Thyroid hormones stimulate general metabolism and new feather growth (Webster et al., 2016). Additional causes for the change in the thyroid gland including normal molting and/or exposure to environmental goitrogenic substances should have resulted in similar changes across both groups (BaJaJ et al., 2016).

5. Conclusions

Significant gross and/or histopathologic lesions were induced in the kidney, heart, pancreas, thyroid, and possibly liver by either oral or dermal exposure of DCCO to weathered MC252 crude oil. The renal lesions (collecting duct and renal tubule epithelial hypertrophy, periductular and peritubular inflammation, squamous metaplasia and renal mineralization) expected in the orally-dosed birds based on published literature, were recognized in this study. These changes over time could significantly impair the kidneys' ability to excrete waste and maintain electrolyte and solute homeostasis as evidenced by uremia and uraemia, thereby causing morbidity or mortality. The significance of the cardiac changes found upon gross examination of the orally and dermally exposed birds was confirmed by antemortem functional testing. Minimal histologic change was detected in the heart indicating that standard histologic techniques may not be an appropriate diagnostic tool for determining oil-induced cardiac damage. Cytoplasmic vacuolation of pancreatic exocrine cells and zymogen depletion increased in the orally exposed birds in comparison to the control birds supporting toxic exposure. The functional significance of the pancreatic lesions and potential to impact health and induce mortality were not explored in this study. In the dermally exposed birds, an increased number of birds had thyroid gland lesions which may be directly induced by components of weathered MC252 crude oil or secondary to feather damage and increased need for metabolic heat production. While the histologic changes in the liver were minimal and likely represent a false negative, the change in organ weight combined with biochemical changes (Dean et al., 2017; Pritsos et al., 2017) indicate that the liver was also damaged. Results of the present study suggest that oral or dermal exposure of DCCOs to artificially weathered MC252 crude oil induced organ damage that could adversely affect survivability.

Acknowledgements

The studies appearing in this special issue were funded by the U.S. Fish and Wildlife Service (Order No. F12PD01069) as part of the Deepwater Horizon Natural Resource Damage Assessment. Thanks to Dr. Jennifer Brazzell for quality assurance of the histopathology and Dr. Allan Pessier for critical review of this manuscript.

References

- BaJaJ, J.K., Salwan, P., Salwan, S., 2016. Various possible toxicants involved in thyroid dysfunction: a review. *J. Clin. Diagn. Res.: JCDR* 10 (1), FE01.

- Bursian, S.J., Dean, K.M., Harr, K.E., Kennedy, L., Link, J.E., Maggini, I., Pritsos, C., Pritsos, K.L., Schmidt, R.E., Guglielmo, C.G., 2017. Effect of oral exposure to artificially weathered Deepwater Horizon crude oil on blood chemistries, hepatic antioxidant enzyme activities, organ weights and histopathology in western sandpipers (*Calidris mauri*). *Ecotoxicol. Environ. Saf* (this issue).
- Cunningham, F.L., Dean, K.M., Hanson-Dorr, K.C., Harr, K.E., Healy, K., Horak, K.E., Link, J.E., Shriner, S., Rupp, T.L., Bursian, S.J., Dorr, B.S., 2017. Development of methods for avian oil toxicity studies using the double crested cormorant (*Phalacrocorax auritus*). *Ecotoxicol. Environ. Saf* (this issue).
- Dean, K.M., Bursian, S.J., Cacula, D., Carney, M.W., Cunningham, F.L., Dorr, B., Hanson-Dorr, K.C., Healy, K.A., Horak, K.E., Link, J.E., Lipton, I., McFadden, A.K., McKernan, M.A., Harr, K.E., 2017. Changes in white cell estimates and plasma chemistry measurements following oral or dermal dosing of double crested cormorants, *Phalacrocorax auritus*, with artificially weathered MC252 oil. *Ecotoxicol. Environ. Saf* (this issue).
- Deepwater Horizon Natural Resource Damage Assessment Trustees, 2016. *Deepwater Horizon Oil Spill: Final Programmatic Damage Assessment and Restoration Plan and Final Programmatic Environmental Impact Statement*. Retrieved from <<http://www.gulfspillrestoration.noaa.gov/restoration-planning/gulf-plan/>>.
- Duerr, R.S., 2013. Investigation into Nutritional Condition and Digestive Capabilities of Seabirds during Rehabilitation in California (Ph.D. Dissertation). University of California, Davis.
- Forth, H.P., Mitchelmore, C.L., Morris, J.M., Lay, C.R., Lipton, J., 2017. Characterization of dissolved and particulate phases of water accommodated fractions used to conduct aquatic toxicity testing in support of the Deepwater Horizon natural resource damage assessment. *Environ. Toxicol. Chem.* 36 (6), 1460–1472.
- Fry, D.M., Lowenstine, L.J., 1985. Pathology of common murre and Cassin's auklets exposed to oil. *Arch. Environ. Contam. Toxicol.* 14, 725–737.
- Giordano, F.J., 2005. Oxygen, oxidative stress, hypoxia, and heart failure. *J. Clin. Invest.* 115 (3), 500–508.
- Harr, K.E., Cunningham, F.L., Pritsos, C.A., Pritsos, K.L., Muthumalage, T., Dorr, B.S., Horak, K.E., Hanson-Dorr, K.C., Dean, K.M., Cacula, D., Link, J.E., Healy, K., Tuttle, P., Bursian, S.J., 2017a. Weathered MC252 crude oil-induced anemia and abnormal erythroid morphology in double-crested cormorants (*Phalacrocorax auritus*) with light microscopic and ultrastructural description of Heinz bodies. *Ecotoxicol. Environ. Saf* (this issue).
- Harr, K.E., Rishniw, M., Rupp, T.L., Cacula, D., Dean, K.M., Dorr, B.S., Hanson-Dorr, K.C., Healy, K., Horak, K., Link, J.E., Reavill, D., Bursian, S.J., Cunningham, F.L., 2017b. Dermal exposure to weathered MC252 crude oil results in echocardiographically identifiable systolic myocardial dysfunction in double crested cormorants (*Phalacrocorax auritus*). *Ecotoxicol. Environ. Saf* (in press).
- Holmes, W.N., Cavanaugh, K.P., Cronshaw, J., 1978. The effects of ingested petroleum on oviposition and some aspects of reproduction in experimental colonies of mallard ducks (*Anas platyrhynchos*). *J. Reprod. Fertil.* 54, 335–347.
- Khan, R.A., Nag, K., 1993. Estimation of hemosiderosis in seabirds and fish exposed to petroleum. *Bull. Environ. Contam. Toxicol.* 50, 125–131.
- Landman, W.J.M., Gruys, E., Gielkens, A.L.J., 1998. Avian amyloidosis. *Avian Pathol.* 27, 437–449.
- Leighton, F.A., 1986. Clinical, gross, and histological findings in herring gulls and Atlantic puffins that ingested Prudhoe Bay crude oil. *Vet. Pathol.* 23, 254–263.
- Maggini, I., Kennedy, L.V., Bursian, S.J., Dean, K.M., Gerson, A.R., Harr, K.E., Link, J.E., Pritsos, C.A., Pritsos, K.L., Guglielmo, C.G., 2017. Toxicological and thermoregulatory effects of feather contamination with artificially weathered MC 252 oil in western sandpipers (*Calidris mauri*). *Ecotoxicol. Environ. Saf* (this issue).
- Mazet, J.A.K., Newman, S.H., Gilardi, K.V.K., Tseng, F.S., Holcomb, J.B., Jessup, D.A., Ziccardi, M.H., 2002. Advances in oiled bird emergency medicine and management. *J. Avian Med. Surg.* 16, 146–149.
- Miller, D.S., Peakall, D.B., Kinter, W.B., 1978. Ingestion of crude oil: sublethal effects in herring gull chicks. *Science* 199, 315–317.
- Olson, J.M., McNabb, F.M., Jablonski, M.S., Ferris, D.V., 1999. Thyroid development in relation to the development of endothermy in the red-winged blackbird (*Agelaius phoeniceus*). *Gen. Comp. Endocrinol.* 116, 204–212.
- Olsford, M.L., Bortolotti, G.R., Trask, B.R., Smits, J.E., 2008. Effects of inhalation exposure to a binary mixture of benzene and toluene on vitamin A status and humoral and cell-mediated immunity in wild and captive American kestrels. *J. Toxicol. Environ. Health A* 71 (16), 1100–1108.
- Pattee, O.H., Franson, J.C., 1982. Short-term effects of oil ingestion on American kestrels (*Falco sparverius*). *J. Wildl. Dis.* 18, 235–241.
- Peakall, D.B., Norstrom, R.J., Jeffrey, D.A., Leighton, F.A., 1989. Induction of hepatic mixed function oxidases in the herring gull (*Larus argentatus*) by Prudhoe Bay crude oil and its fractions. *Comp. Biochem. Physiol.* 94C, 461–463.
- Pritsos, K.L., Perez, C.R., Muthumalage, T., Dean, K.M., Cacula, D., Hanson-Dorr, K.C., Cunningham, F.L., Bursian, S.J., Link, J.E., Shriner, S., Horak, K.E., Pritsos, C.A., 2017. Dietary intake of deepwater horizon oil-injected live food fish by double-crested cormorants resulted in oxidative stress. *Ecotoxicol. Environ. Saf* (this issue).
- Sileo, L., Beyer, W.N., Mateo, R., 2003. Pancreatitis in wild zinc-poisoned waterfowl. *Avian Pathol.* 32, 655–660.
- Szaro, R.C., Albers, P.H., Coon, N.C., 1978. Petroleum: effects on mallard egg hatchability. *J. Wildl. Manag.* 42, 404–406.
- Webster, R.K., Aguilar, R.F., Argandona-Gonzalez, A.-K., Conayne, P., De Sousa, D., Sriram, A., Svensson, C.M., Gartrell, B.D., 2016. Forced molt in four juvenile yellow-eyed penguins (*Megadyptes antipodes*). *J. Wildl. Dis.* 52 (4), 809–816. <http://dx.doi.org/10.7589/2015-11-305>.
- Yamato, O., Goto, I., Maeda, Y., 1996. Hemolytic anemia in wild seaducks caused by marine oil pollution. *J. Wildl. Dis.* 32, 381–384.